

# ALGORITHMS FOR MAMMOGRAM ANALYSIS

## A FOCUS ON BREAST TISSUE ASYMMETRY

Craig D.M. Henderson  
craig2.henderson@uwe.ac.uk

### Breast Cancer Facts

- Heterogeneous disease
- Cause unknown
- Most frequently diagnosed non-skin cancer
- Accounts for 30% of cancer cases detected [1]
- In the UK, 1 in 3 of all cancer cases are breast cancer [2]
- Nearly 41,000 new cases diagnosed each year

### Mammography

- Effective non-invasive inspection of internal breast tissue
- Low dose radiation
- High contrast, high resolution film
- Digital mammogram is becoming more common
- Large images; 4096 pixels square, 16 bit colour = 32Mb per image

### Research Goals

It has been suggested that asymmetry in bilateral breast X-ray images may be indicative of early stage cancer. This research project aims to investigate the significance of asymmetric features in such mammogram images with a view to improving the detection and differentiation of malignant masses, micro-calcifications and other early indications such as architectural distortions.

### Bilateral Tissue Comparison

- Asymmetry between contralateral breasts is an important sign used by radiologists to diagnose breast cancer [3, 4]
- Recent thought is that asymmetric breast tissue is nearly always regarded as benign [5, 6]
- Contralateral comparison of linear structures
  - Width and Orientation
  - Local Curvature
  - Branch Points
- Vasculature in the breast is generally symmetrical in size and distribution. An asymmetrically large vein may indicate an abnormality [1]

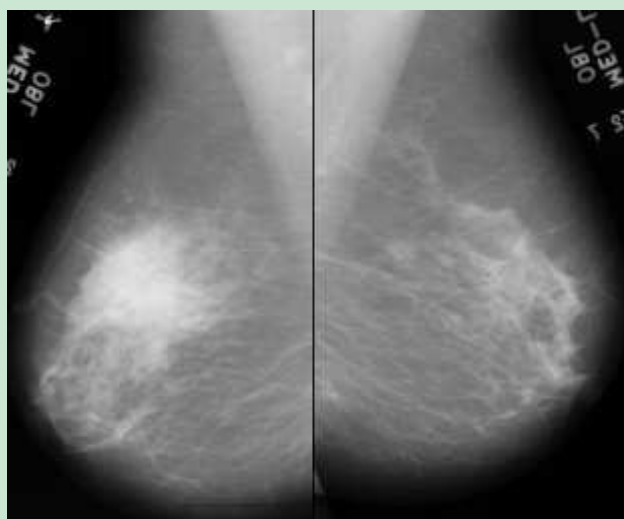


Figure 1 - bilateral mediolateral oblique mammogram images

### Image Orientation

All mammogram image processing algorithms are simplified if they can be designed to operate on a single orientation of an image. The goal of the image orientation task is to identify a mammogram image as a left or right breast to enable the system to accept either image as input and automatically re-orient the image before processing.

This initial image orientation problem is generally omitted from the image registration procedure and left to the operator to provide the X-ray images in the order and orientation that the software system requires. In a fully automated system, this is an unacceptable burden on the system operator. This research developed an algorithmic procedure for identifying the orientation of mediolateral oblique breast images that can be used as a first step in the process of mammogram registration in an automated system.

Henderson, C.D.M., August 2003, *Automated identification of the orientation of mediolateral oblique mammographic images* [Unpublished]

### Global Segmentation

A mediolateral oblique (MLO) mammogram image contains far more than just an image of the breast. A film clip is generally present along with imaging artefacts and background noise. Before any computer analysis of the mammogram begins, the identification and extraction of the breast area is necessary - a technique called *global segmentation*. This research developed a fully automated algorithm for global segmentation of MLO mammograms to create an accurate breast region without user intervention.

Henderson, C.D.M., Smith, J.E., Solomonides, A.E., May 2005, *Automated global segmentation of mediolateral oblique mammographic images* [Unpublished]

### Local Segmentation

Local Segmentation describes the process of breast area decomposition, specifically in removing the pectoral muscle from the breast area leaving only soft tissue in the image. It is in this soft tissue that cancer indicators are found. The shape of the pectoral muscle can vary depending on imaging conditions; in an ideal image, the outline will be convex in shape, in poor images the outline will be concave or not visible at all. In general, the outline can be represented by a straight line. Some researchers use a straight line approximation, and others strive for a more accurate representation.

Local segmentation is the current research activity in this project.

### Feature Extraction and Analysis

The breast tissue structure is complex and mammograms contain a number of texture patterns. This complexity makes

# ALGORITHMS FOR MAMMOGRAM ANALYSIS

## A FOCUS ON BREAST TISSUE ASYMMETRY

Craig D.M. Henderson  
craig2.henderson@uwe.ac.uk

the analysis a difficult job for trained professional radiologists and a big challenge for automated computer systems. Any mammogram contains a variety of linear structures, such as

- Vessels
- Ducts
- Fibrous tissue
- Skin folds

In abnormal mammograms, linear structures called *spicules* may also be present. Abnormalities in breast tissue are, in the main, related to linear structures. For example, the significance of microcalcifications located within ducts is greater than those that are not, and spicules are always associated with lesions (called *spiculated lesions*) [7].

### WinMammo

All algorithms in this research project are developed in C++, and a host application has been developed to display the mammogram images and allow the user to interactively apply image processing algorithms and immediately see the results on screen. This application has been called WinMammo.

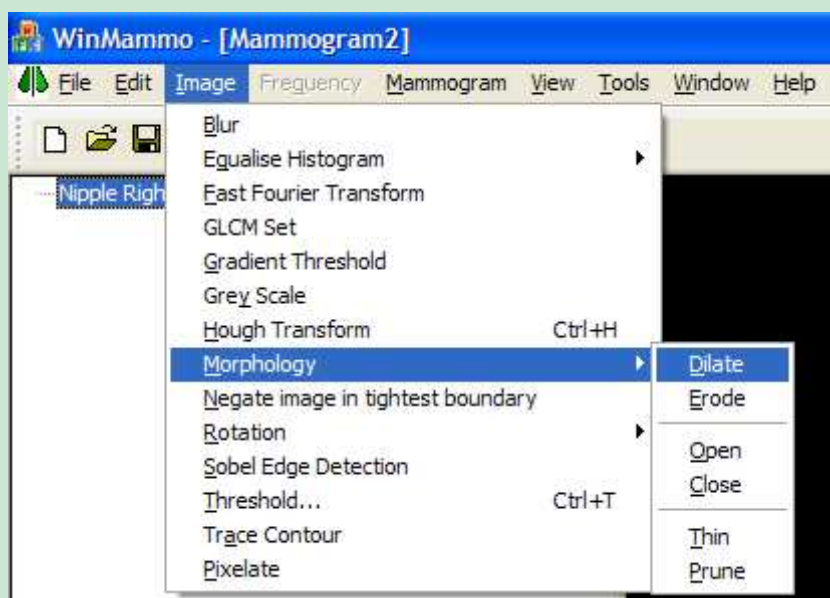


Figure 2 - Interactive image processing functions make comparisons easy

WinMammo reads the truth data supplied with the MIAS and MiniMIAS mammogram databases, and displays the information in the Open dialog. This enables the user to identify a specific mammogram abnormality and saves on manual cross-referencing to the data file.

Name	Tissue	Abnormality	Severity	Coords	Radius
mb063	Dense Glandular	Other: ill-defined masses	Benign	546, 463	33
mb069	Fatty	Well-defined/circumscribed masses	Benign	462, 406	44
mb072	Fatty Glandular	Asymmetry	Malignant	266, 517	28
mb075	Fatty	Asymmetry	Malignant	468, 717	23
mb080	Fatty	Well-defined/circumscribed masses	Benign	432, 149	20
mb081	Fatty Glandular	Asymmetry	Benign	492, 473	131
mb083	Fatty Glandular	Asymmetry	Benign	544, 194	38
mb090	Fatty Glandular	Asymmetry	Malignant	510, 547	49
mb091	Fatty	Well-defined/circumscribed masses	Benign	680, 494	20
mb092	Fatty	Asymmetry	Malignant	423, 662	43
mb095	Fatty	Asymmetry	Malignant	466, 517	29
mb097	Fatty	Asymmetry	Benign	612, 297	34
mb099	Dense Glandular	Asymmetry	Benign	714, 340	23
mb102	Dense Glandular	Asymmetry	Malignant	415, 460	38
mb104	Dense Glandular	Asymmetry	Benign	357, 365	50
mb105	Dense Glandular	Asymmetry	Malignant	516, 279	98

Figure 3 - Open dialog provides diagnosis truth data

The intensity frequency distribution is an important facet in analysing mammogram images. WinMammo provides a floating intensity histogram display window that is dynamically

updated as a new mammogram is displayed. The histogram can be customised to display the information in a number of ways to give the user control over the presentation to aid the work.

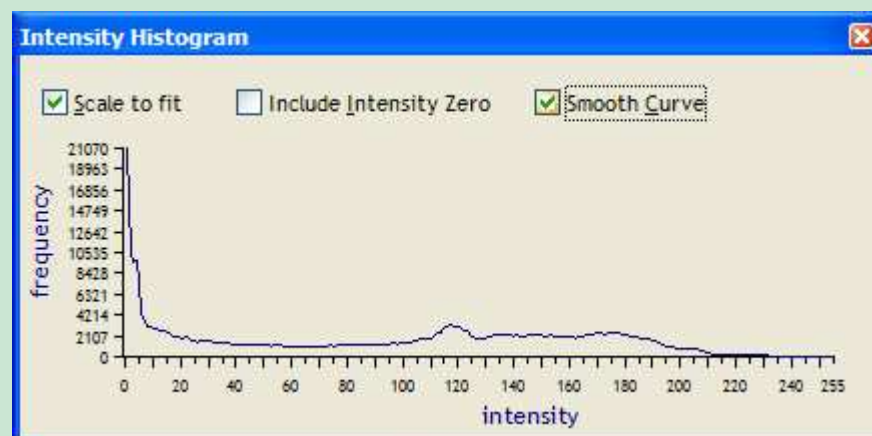


Figure 4 - Histogram window plots intensity frequencies

MLO images are inherently portrait in appearance. This can be inconvenient in some environments, such as a machine with a wide screen display, so WinMammo provides a *Wide Screen* mode of operation where the display of the image is rotated such that the nipple is always facing upward.

As algorithms are applied to an image, WinMammo adds an entry to the tree view on the left hand side of the main window, describing the algorithm, and any parameters that were set. This enables easy onscreen comparison of results, and the tree provides a means of identifying the set of algorithms applied to an image to achieve a result.

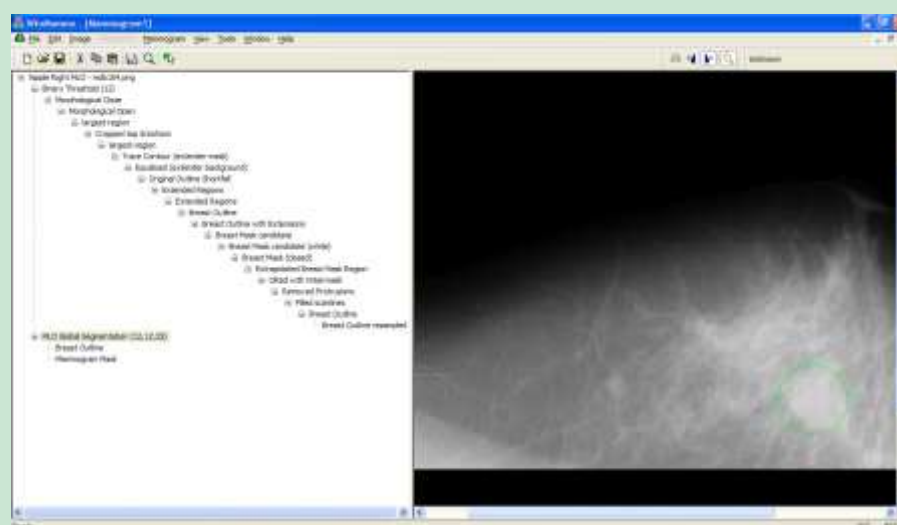


Figure 5 - Intermediate working images can be kept for algorithm comparison

### References

1. Cardenosa, G., 2001, *Breast Imaging Companion*, Lippincott Williams & Wilkins, 495 pages.
2. Cancer Research UK, 2004 (05/08/2004), Online at <http://www.cancerresearchuk.org/aboutcancer/specificcancer/breastcancer>
3. Miller, P. and Astley, S., 1993, *Automated detection of mammographic asymmetry using anatomical features*, International Journal of Pattern Recognition and Artificial Intelligence 7 (6), pp. 1461-1476.
4. Ferrari, R.J., Rangayyan, R.M., Desautels, J.E.L. and Frere, A.F., 2001, *Analysis of asymmetry in mammograms via directional filtering with Gabor wavelets*, IEEE Transactions on Medical Imaging 20 (9), pp. 953-964.
5. Apgar, B., 1999, *Is Asymmetric Breast Tissue a Sign of Malignancy*, American Family Physician.
6. Piccoli, C.W., Feig, S.A. and Palazzo, J.P., 1999, *Developing Asymmetric Breast Tissue*, Radiology 211 pp. 111-117.
7. Zwiggelaar, R. and Boggis, C.R.M., 2002, *The Benefit of Knowing Your Linear Structures in Mammographic Images*, Proc. of Medical Image Understanding and Analysis.